



Original research

Intraoperative Assessment of Stability in Total Hip Arthroplasty: A Novel Method Utilizing Implant Collinearity

Nathan T. Underwood, MBBS, MTraum ^{a, b, c},
Chameka Madurawe, BEng (Hons) (Biomedical) ^{a, b, c}, Lyal A. Ashton, MBBS ^{a, b, c, *}

^a Department of Orthopaedic Surgery, Orange Health Service, Orange, New South Wales, Australia

^b Corin Australia Pty Ltd., Pymble, New South Wales, Australia

^c Orthopaedic Department, Dudley Private Hospital, Orange, New South Wales, Australia

ARTICLE INFO

Article history:

Received 4 September 2023

Accepted 4 November 2023

Available online 25 January 2024

Keywords:

Hip
Arthroplasty
Acetabulum
Position
Stability
Collinear

ABSTRACT

Background: Hip dislocation remains a leading cause of revision following total hip arthroplasty, and intraoperative assessment of acetabular positioning can be difficult to perform. There are multiple clinical tests, as well as computer and robotic techniques, that aim to reduce dislocation rates after hip arthroplasty. These approaches aim to optimize the relationship between acetabular and femoral component positioning. It is hypothesized in this study that implant collinearity assessment intraoperatively can help determine appropriate acetabular component position. More specifically, implant collinearity, when achieved with a specific leg position, can reliably predict appropriate acetabular positioning.

Methods: A single-surgeon, single-centered study with 55 patients was undertaken between August 2017 and March 2020. Using preoperative imaging and computer simulation, data points were taken for 3 different acetabular configurations and comparing using 2 femoral positions. The angle differences from the collinear position (0 degrees) were compared between groups.

Results: A total of 55 patients' imaging was analyzed using 3 acetabular configurations and 2 femoral positions. The test leg position (30-degree flexion/30-degree internal rotation/10-degree adduction) was closer to collinearity than the control position (30-degree flexion/30-degree internal rotation/0-degree adduction) in all 3 acetabular configurations by a mean of 8 degrees ($P < .001$), 7 degrees ($P < .001$), and 4 degrees ($P < .001$), respectively.

Conclusions: The use of a 10-degree adducted position more reliably recreates implant collinearity when determining acetabular positioning during total hip arthroplasty. This intraoperative test adds another data point to assist the surgeon in achieving safe component positioning.

© 2023 The Authors. Published by Elsevier Inc. on behalf of The American Association of Hip and Knee Surgeons. This is an open access article under the CC BY-NC-ND license (<http://creativecommons.org/licenses/by-nc-nd/4.0/>).

Introduction

Total hip arthroplasty (THA) is one of the most successful procedures performed by orthopedic surgeons regarding patient satisfaction. In Australia, there were approximately 49,000 primary THAs performed in 2020 [1]. In patients receiving THA for osteoarthritis, dislocation/instability remains the most frequent reason for revision in the first 11 years after surgery. Loosening is the

dominant reason for revision after 11 years. The 20-year revision rate after a THA is 9.0%, and dislocation accounts for 22.5% of this figure [1]. According to the Australian Orthopaedic Association National Joint Replacement Registry, there is a higher rate of revision for dislocation in patients receiving a THA via a posterior approach than an anterior approach [1]. Fleischman et al. found that clinically significant instability was more frequent in patients with THA performed through a posterolateral surgical approach than through anterior and lateral approaches [2]. More recently, Huerfano et al. showed no statistical difference in dislocation rates between a posterior approach and direct anterior approach [3].

One of the oldest theories behind dislocation occurrence relates to component positioning outside of a "safe zone." Lewinnek et al.

* Corresponding author. Orange Health Service, 309 March Street, Orange, New South Wales 2800, Australia. Tel.: +61 2 6360 1500.

E-mail address: laashton@oso.com.au

[4] proposed a range of acetabular orientations that would reduce the risk of dislocation after arthroplasty. This safe zone theory was first discussed in 1978 and has been debated and subsequently revised on numerous occasions with no current clear consensus on a specific safe zone. Other theories have emerged, which discuss combined anteversion measurements, functional safe zones, and patient-specific safe zones.

Achieving desired acetabular orientations intraoperatively is not straightforward. There are many methods to assess acetabular orientation intraoperatively, with each having their limitations. One frequently utilized method is the use of a mechanical guide attached to the acetabular component introducer. This allows angle assessment of cup orientation with respect to the position of the patient. The guides are usually manufactured at 45 and 20 degrees of acetabular inclination and anteversion, respectively. These guides can be used in tandem with various computer navigation or robotic methods to further increase precision. Patient landmarks such as the native acetabular bony anatomy and the transverse acetabular ligament aid in acetabular positioning. These anatomical patient landmarks may help the surgeon compensate for errors in acetabular cup positioning related to imperfect patient positioning relative to the operating table, and intraoperative patient movement that may occur during the procedure. Significant degenerative hip disease can make identification and subsequent reliance on these anatomical landmarks problematic. Dynamic stability testing intraoperatively can be conducted by the surgeon to help determine implant stability when trialing hip arthroplasty components. Hip stability and impingement during range-of-motion testing at the trial stage of the procedure are traditionally assessed in flexion plus internal rotation and extension plus external rotation, as described by Harris [5]. Combined anteversion can be assessed as per a method described by Ranawat and Maynard [6]. This is achieved by internally rotating the hip while the leg is in neutral flexion/extension until the prosthetic neck and acetabular face become perpendicular. The degree of internal rotation of the hip at that point is termed combined anteversion.

Ranawat and Maynard [6] also described positioning the hip while flexed at 30 degrees and adducted 10 degrees and internally rotating to assess hip stability. It has been anecdotally noted that by internally rotating the hip to 30 degrees and maintaining 30 degrees of hip flexion and 10 degrees of adduction, the prosthetic head and the acetabular face should be perpendicular for ideal and safe component positioning. In this position, the acetabular face and the flat under-surface of the prosthetic femoral head should be collinear.

There are a multitude of intraoperative clinical assessments that may be used by the surgeon to help achieve accurate THA component positioning. Collinearity measurements are one such assessment that may help the surgeon understand the relationship between the acetabular and femoral components and help predict hip stability postoperatively. For example, if the components are not close to collinear with appropriate leg positioning, it is more likely that one or both components have been placed incorrectly. This would deem the patient at higher risk of THA instability, prosthetic or bony impingement, and abnormal wear, thereby increasing the likelihood of a poor outcome that may require revision.

Our study aims to assess the accuracy and utility of this anecdotal test in terms of ideal THA component positioning using simulated computer modeling techniques. A series of patients' hips were positioned using 3D computer simulation at 30 degrees of flexion, 30 degrees of internal rotation, and 10 degrees of adduction (30/30/10) and assessed for component collinearity positioning at 3 specific acetabular inclination and anteversion positions. The

patient's native femoral anteversion measurements were unchanged in this simulation. This 30/30/10 hip position was compared with positioning the hips at 30 degrees of flexion, 30 degrees of internal rotation, and no adduction (30/30/0) with regards to achieving component collinearity. The hypothesis generated was that the 30/30/10 position would be closer to collinear than the 30/30/0 position. Specific attention was given to assess how close to collinear the components were in the 3 different acetabular positions.

This generated a primary and secondary research questions. First, was the test position (30/30/10) closer to collinear than the control position (30/30/0), and did this test confirm 'accurate' acetabular positioning when collinearity was achieved?

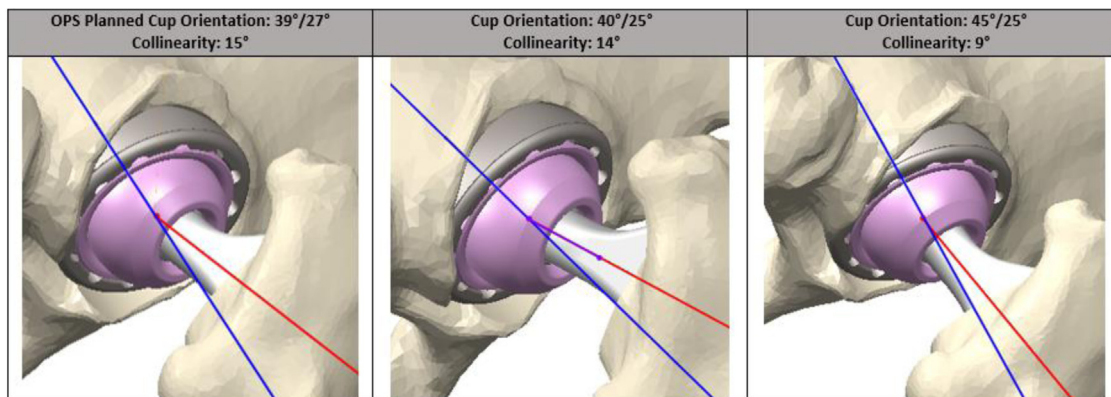
Material and methods

This single-surgeon (L.A.A.), single-centered study was undertaken between August 2017 and March 2020. Fifty-five consecutive patients requiring primary THA were recruited. Ethics approval was obtained by the Greater Western Human Research Ethics Committee, New South Wales, Australia. As part of routine preoperative assessment and surgical planning, patients received sitting, standing, and step-up lateral radiographs of the pelvis and a pelvic computed tomography scan, in addition to standard radiographs. These data were analyzed through the Corin Optimised Positioning System [7] (OPS) to determine the ideal acetabular component orientation. The femoral component version was recorded and planned to remain unaltered from the patient's native femoral version. OPS analysis then produced a patient-specific functional range-of-motion assessment to determine prosthetic loading, impingement, and instability. At this stage, the data were de-identified for the purpose of this study. Data points were recorded with the patient's femur oriented in both the 30/30/10 and 30/30/0 positions for 3 acetabular positionings with respect to inclination/anteversion. The 3 simulated positions were as follows: acetabular component 40 degrees inclination/25 degrees anteversion, 45 degrees inclination/25 degrees anteversion, and the ideal OPS determined acetabular inclination and anteversion for that patient. The number of degrees away from collinearity in each of these 3 positions was recorded in the 2 different femoral positions (30/30/10 and 30/30/0) (Figs. 1 and 2). We had no expectation that the individualized OPS acetabular positioning recommendations would be closer to collinear than the other positions measured. In fact, our study allowed an independent comparison between these 3 positions for collinearity assessment. The planned femoral stem anteversion was matched with the native femoral anteversion and was recorded. These data were collated and analyzed using Stata (V 17.0 Basic Edition, StataCorp LLC, College Station, TX). A Wilcoxon signed-rank test for dependent samples was conducted to determine the difference between the mean collinearity angle away from zero for the 2 groups with respect to hip positioning across the 3 simulated acetabular positions. A 10-degree variance from collinearity was determined as the minimum detectable clinical change for this study. The alpha value was set at 5%, and the beta value set at 80%.

Results

During the recruitment period of 2.5 years, the surgeon (LAA) performed 55 THAs with OPS analysis. There were 32 right-sided THAs completed, and 23 left sided. There were no simultaneous bilateral THAs included. OPS analysis was completed for each patient, with full data points recorded for the simulated acetabular positions. One patient did not have their femoral anteversion

1. Test 1: 30° of flexion and 30° of IR (no adduction)



2. Test 2: 30° of flexion, 30° of IR and 10° of adduction

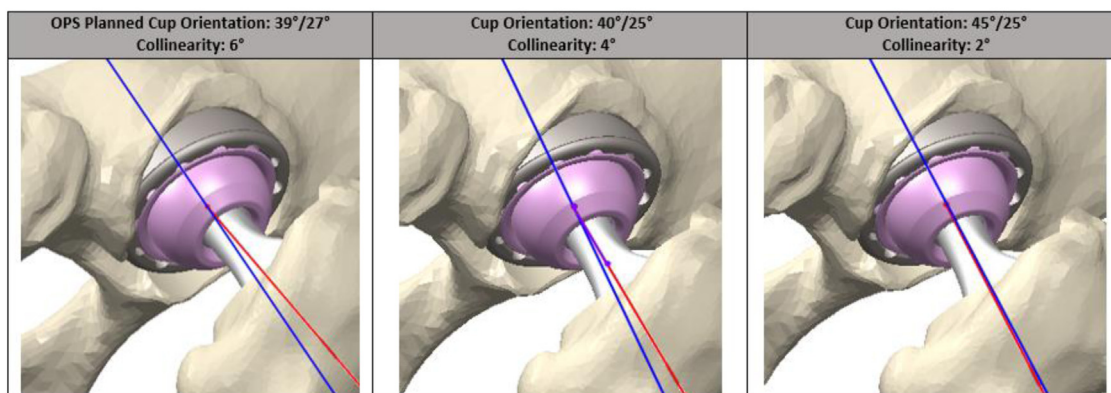


Figure 1. Collinearity assessment in a Patient for a Left Total Hip Arthroplasty.

recorded. The ideal OPS determined acetabular positions, and femoral anteversion is displayed in Table 1. The angle away from collinearity for the 3 acetabular orientations with the hip examined in 30/30/0 and 30/30/10 is displayed in Table 2. A post-hoc power analysis was completed, showing a minimum number per group of 64.

The 30/30/10 test was closer to collinear in the tested acetabular configurations than the 30/30/0 test ($P < .001$). The 30/30/10 test was 5 degrees closer than 30/30/0 when comparing the OPS acetabular configurations ($P < .001$). It was also 5 degrees closer when comparing the 40/25 acetabular configuration ($P < .001$), and 4 degrees closer with the 45/25 acetabular configuration ($P < .001$). Across the 3 chosen acetabular positions (OPS, 40/20, and 45/25), when the leg was positioned at 30/30/10, the mean was 9 degrees, median 7, and range 0-31 degrees. With the leg in 30/30/0 across the 3 acetabular positions, the corresponding mean was 14, median 13, and range 2-26. This was in keeping with the generated hypothesis.

The 45/25 position was closer to collinear in the 30/30/10 leg position than both the 40/25 and the OPS "ideal" positions. In the 45/25 position, the mean was 7 degrees/median 6, range 0-22 degrees. The 40/25 by comparison had a mean angle of 9, median 7, and range 1-26 degrees. The OPS "ideal" position had a mean of 10, median 8, and range 1-31 degrees.

The 45/25 position was also closer to collinear in the 30/30/0 leg position than both the 40/25 and the OPS recommended positions. In the 45/25 position, the mean 11 degrees/median 10, range 2-21 degrees. The 40/25 position had a mean angle of 15, median 14, and range 6-24 degrees. The OPS "ideal" position; mean 16, median 16, and range 5-26 degrees.

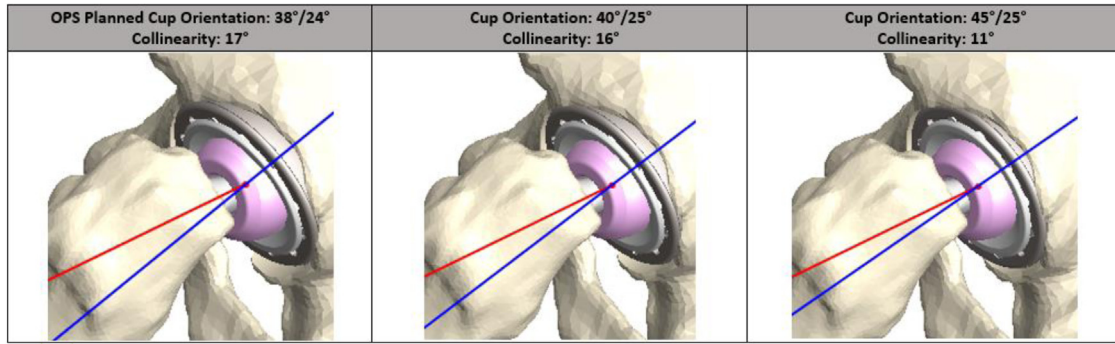
Discussion

Based on our results, we found that examining hip component collinearity intraoperatively in the 30/30/10 position was more accurate than the 30/30/0 position. This finding adds scientific rigor to what has been until now an anecdotal test frequently used by surgeons intraoperatively. These findings provide surgeons with greater confidence that if component collinearity is achieved with appropriate leg positioning, then ideal planned THA component orientation should also be achieved (close to 45/25), helping mitigate the risk of prosthetic dislocation and impingement and hopefully maximizing component longevity.

Both tested leg positions confirmed that the 45/25 acetabular position was closer to collinear than 40/25 and OPS "ideal" positioning. We therefore predict that if collinearity has been achieved with the correct leg positioning, acetabular configuration will be close to 45/25 in most patients.

To our knowledge, this is the first study that uses a simulated intraoperative prosthetic articulating surface collinearity test to determine acetabular positioning with respect to predetermined targets. Ranawat and Maynard [6] discussed using a version of collinearity testing when assessing for combined anteversion. His test was described with the hip in neutral flexion extension with increasing internal rotation until collinearity was achieved, thereby giving the combined component anteversion. In Ranawat's described clinical test, he did not discuss hip adduction. Furthermore, the senior author has found the utility of Ranawat's test is limited; the hip can feel tight when positioned in extension with increasing internal rotation (even when retractors are removed).

1. Test 1: 30° of flexion and 30° of IR (no adduction)



2. Test 2: 30° of flexion, 30° of IR and 10° of adduction

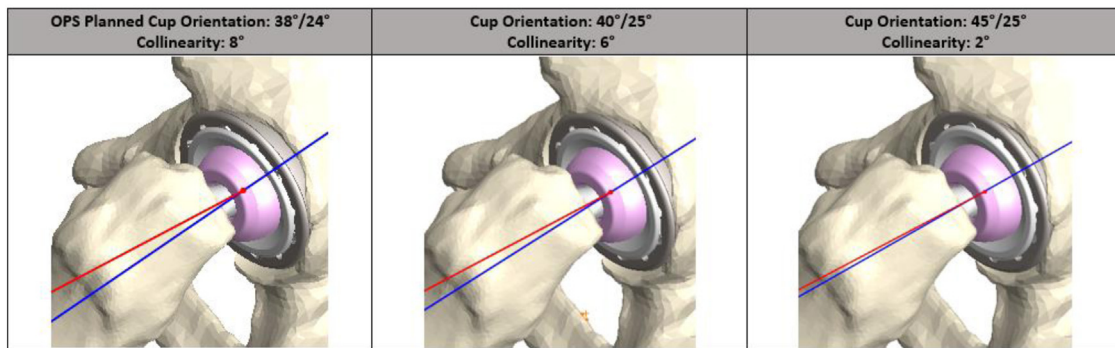


Figure 2. Collinearity assessment in aPatient for a Right Total Hip Arthroplasty.

Second, the view afforded in this position is significantly more limited than in the 30/30/10 position. Judging collinearity is hence more challenging and likely less accurate.

After Ranawat’s article, Blumenfeld [8] discussed the utility of the Ranawat test with respect to acetabular inclination when measuring with the hip in neutral extension and 45 degrees internal rotation. Blumenfeld stated that if the prosthetic femoral neck shaft angle has been designed by the company at 135 degrees, and intraoperatively the iliac crests are directly above one another and perpendicular to the floor, then if collinearity is achieved, acetabular inclination will be 45 degrees. Blumenfeld’s test only addresses inclination not anteversion.

We recognize that there are multiple risk factors surrounding THA instability. Previously, it was reported that the posterior approach had a higher rate of revision for dislocation than other approaches. Fleischman et al [2] reported an increased risk of dislocation with the posterolateral approach when compared with both the direct lateral and direct anterior approaches for the first 2 years following THA. A recent large registry-based observational study out of Sweden [9], however, did not find any statistically significant difference for reoperation rates for THA dislocation performed via the posterior approach when compared with the direct lateral approach. This contrasted with a previous audit from

the same registry taken a decade earlier [10]. The more recent Swedish registry-based study reported that the then routine use of head sizes larger than 28 mm, as well as refinements in surgical technique, were contributing factors in reducing the gap in dislocation rates between the posterior and direct lateral approaches. A meta-analysis by Kwon et al. [11] showed comparable dislocation rates for the major surgical approaches used in THA, except when the posterior approach was used without a capsular repair (which led to a significantly greater relative risk for dislocation). A 2021 meta-analysis [3] found no difference regarding instability rates when comparing posterolateral and direct anterior approaches. In our study, LAA performed THA utilizing a posterior approach with capsular repair. Long-term dislocation rates in this cohort are yet to be established.

While there remains no consensus, several studies have examined optimal “safe zones” for acetabular component positioning. Lewinnek et al. [4] stated there is a relatively safe range for acetabular cup orientation: 40 ± 10 degrees of abduction and 15 ± 10 degrees of anteversion. Later, McCollum and Gray [12] revised this to 40 ± 10 abduction and 30 ± 10 anteversion. More recently, researchers have attempted to challenge and redefine these safe zones [13-15]. Abdel et al. [16] found that an acetabular component implanted using a posterior approach was 3 times as

Table 1
OPS ideal positioning and femoral anteversion.

	OPS ideal acetabular anteversion	OPS ideal acetabular inclination	Femoral anteversion
Mean	23.6 degrees	40.1 degrees	14.3 degrees
Median	24 degrees	39 degrees	14 degrees
Range	12-39 degrees	37-45 degrees	1-30 degrees
SD	5.2 degrees	2.4 degrees	6.9 degrees

Table 2
Angles away from collinearity.

Angle away from collinearity	OPS ideal	40 degrees inclination/25 degrees anteversion	45 degrees inclination/25 degrees anteversion	All positions
30/30/0				
Median	16 degrees	14 degrees	10 degrees	13 degrees
Mean	15.47 degrees	14.55 degrees	10.51 degrees	13.51 degrees
Range	5-26 degrees	6-24 degrees	2-21 degrees	2-26 degrees
30/30/10				
Median	8 degrees	7 degrees	6 degrees	7 degrees
Mean	9.98 degrees	8.58 degrees	7.42 degrees	8.66 degrees
Range	1-31 degrees	1-26 degrees	0-22 degrees	0-31 degrees
Difference	8 degrees ($P < .001$)	7 degrees ($P < .001$)	4 degrees ($P < .001$)	6 degrees ($P < .001$)

likely to be within these safe zones compared with the antero-lateral approach but still had an increased risk for dislocation. Biedermann et al. [15] reported on a consistent relationship between anteversion and the direction of dislocation, with 15 degrees of anteversion reported as having an equal relative frequency for anterior and posterior dislocations. These studies highlight the fact that there is no single sweet spot when using the posterior approach. In our study, the mean OPS recommended an acetabular abduction position of 40.1 degrees (range 37–45 degrees) and a mean acetabular anteversion of 23.6 degrees (range 12–39), with most individual cases within these previously described safe zones.

It is now 40 years since the concept of a defined acetabular “safe zone” was introduced, and new theories continue to emerge with respect to combined anteversion and functional safe zones. According to Dorr, any reference to a safe zone should incorporate a combined anteversion measurement rather than acetabular anteversion alone [17]. This concept highlights the contribution femoral anteversion adds to THA stability and acknowledges the large variation in native femoral anteversion measurements. Studies by Dorr [17] and Widmer and Zurfluh [18] suggested a safe zone for combined anteversion of $37^\circ \pm 12$ and 37.3 degrees, respectively.

Widmer and Zurfluh [18] continued to discuss a relationship between acetabular anteversion and femoral stem anteversion whereby stem anteversion contributes 70% of combined anteversion (ie, combined anteversion equals acetabular anteversion $+0.7 \times$ femoral stem anteversion), suggesting that acetabular anteversion has a greater contribution than femoral anteversion in hip stability after THA. In our study, planned stem anteversion was aimed to match native femoral anteversion and was quite variable (1.0–30.0 degrees, mean 14.3 degrees) and consistent with a study by Maruyama et al. [19] which showed a large variance in femoral anteversion in 200 hips. The femoral anteversion range measurements in our study (1–30 degrees) are likely the main reason for the similar collinearity range values we discovered (0–31) across all acetabular and leg position groups analyzed and, as such, do not represent a significant confounding factor.

The decision to maintain native femoral anteversion in all cases simulates common intraoperative practice and helps maximize the utility of this test for arthroplasty surgeons. More research could be performed using fixed femoral anteversion to explore these variances in range values detailed above.

The OPS protocol developed by Corin [7] and utilized as pre-operative planning for THA gives its own generated “ideal” acetabular positioning. Intraoperatively, patient-specific instrumentation and laser technology are used to verify acetabular component positioning. This acetabular positioning did not offer any benefits in achieving collinearity in the 30/30/10 or 30/30/0 positions.

The limitations in our study relate to accuracy of leg positioning and judging component collinearity intraoperatively. Interobserver and intraobserver reliability have the potential to be low. There are

multiple angles that the surgeon needs to evaluate in this test, all of which may be difficult to visually assess accurately. It is difficult to position the leg in exactly 30 degrees of flexion, 30 degrees of internal rotation, and 10 degrees of adduction, and at the same time, it is difficult to reliably determine whether the acetabular and femoral components are exactly collinear. It is also difficult to position the patient with their pelvis perfectly square in both planes to provide an accurate basis upon which the angles are derived. There is also a high chance of observer bias; surgeons may overestimate how close their bearing surfaces are to being truly collinear. The use of a small jig appropriately designed and recessed to fit over the femoral head component with a flat surface to sit on the acetabular component may assist in confirming collinearity.

Our study has shown a statistical difference between 30/30/10 and 30/30/0 groups in achieving collinearity, but the clinical difference is negligible, with the largest difference being 8 degrees. The minimum detectable change was set at 10 degrees, which is higher than the largest difference in the simulated tests. These small angles are difficult to see in the intraoperative setting and are likely to be underestimated as an angle closer to zero. The power analysis, based on a minimum detectable change of 10 degrees, was performed after the collection of patient data for our study and shows that the number of patients recruited was below the threshold required to call this study adequately powered. Additional research could be undertaken to validate the findings of this introductory study.

Our computer simulations also were measured as the angle away from zero. This did not take direction into account. The utilization of a vector in this study would make interpretation of the data overly complex and likely add little in terms of component positioning accuracy and test utility. Our study provides scientific rigor to an intraoperative test with high utility that is frequently used but little studied.

Conclusions

Intraoperative evaluation of the orientation of both acetabular and femoral components can be imprecise even with the utility of robotics or navigation. There are multiple methods that the surgeon can use to guide and help in the assessment of component orientation in THA. Each method has its own limitations, but the combination of multiple data points allows confidence that planned component orientation is being achieved. Obvious benefits include a reduction in hip instability, reduction in component impingement, and reduced component edge loading with the possibly of greater THA prosthetic longevity. We advocate for the discussed collinearity test performed in the 30/30/10 leg position, noting that this position is more accurate than the 30/30/0 position with respect to component positioning accuracy. If collinearity is achieved, it should accurately predict acetabular cup positioning of very close to 45/25, thus adding a very useful data point to help the surgeon achieve accurate planned THA component positioning.

Conflicts of interest

C. Madurawe was a paid employee for Corin Orthopaedics Australia during the acquisition and collation of data. All other authors declare no potential conflicts of interest.

For full disclosure statements refer to <https://doi.org/10.1016/j.artd.2023.101282>.

References

- [1] Australian Orthopaedic Association National Joint Replacement Registry (AOANJRR). Hip, knee & shoulder arthroplasty: 2021 annual report. Adelaide: AOA; 2021. p. 1–432.
- [2] Fleischman AN, Tarabichi M, Magner Z, Parvizi J, Rothman RH. Mechanical complications following total hip arthroplasty base on surgical approach: a large, single-institution cohort study. *J Arthroplasty* 2019;34:1255–60. <https://doi.org/10.1016/j.artd.2019.02.029>.
- [3] Huerfano E, Bautista M, Huerfano M, Nossa JM. Use of surgical approach is not associated with instability after primary total hip arthroplasty: a meta-analysis comparing direct anterior and posterolateral approaches. *J Am Acad Orthop Surg* 2021;29:e1126–40. <https://doi.org/10.5435/JAAOS-D-20-00861>.
- [4] Lewinnek GE, Lewis JL, Tarr R, Compere CL, Zimmerman JR. Dislocations after total hip-replacement arthroplasties. *J Bone Joint Surg Am* 1978;60-A:217–20.
- [5] Harris WH. Advances in surgical technique for total hip replacement: without and with osteotomy of the greater trochanter. *Clin Orthop Relat Res* 1980;146:188–204.
- [6] Ranawat CS, Maynard MJ. Modern technique of cemented total hip arthroplasty. *Tech Orthop* 1991;6:17–25.
- [7] Corin optimized positioning system. <https://www.coringroup.com/healthcare-professionals/solutions/optimized-positioning-system-ops/>; 2022. [Accessed 31 May 2022].
- [8] Blumenfeld TJ. Pearls: clinical application of Ranawat's Sign. *Clin Orthop Relat Res* 2017;475:1789–90. <https://doi.org/10.1007/s11999-017-5376-8>.
- [9] Skoogh O, Tsikandylakis G, Mohaddes M, Nemes S, Odin D, Grant P, et al. Contemporary posterior surgical approach in total hip replacement: still more reoperations due to dislocation compared with direct lateral approach? An observational study of the Swedish Hip Arthroplasty Register including 156,979 hips. *Acta Orthop* 2019;90:411–6. <https://doi.org/10.1080/17453674.2019.1610269>.
- [10] Lindgren V, Garellick G, Kärrholm J, Wretenberg P. The type of surgical approach influences the risk of revision in total hip arthroplasty. *Acta Orthop* 2012;83:559–65. <https://doi.org/10.3109/17453674.2012.742394>.
- [11] Kwon MS, Kuskowski M, Mulhall K, Macaulay W, Brown TE, Saleh KJ. Does surgical approach affect total hip arthroplasty dislocation rates? *Clin Orthop Relat Res* 2006;447:34–8. <https://doi.org/10.1097/01.blo.0000218746.84494.df>.
- [12] McCollum DE, Gray WJ. Dislocation after total hip arthroplasty: causes and prevention. *Clin Orthop Relat Res* 1990;261:159–70.
- [13] Danoff J, Bobman J, Cunn G, Murtaugh T, Gorroochurn P, Geller J, et al. Redefining the acetabular component safe zone for posterior approach total hip arthroplasty. *J Arthroplasty* 2016;31:506–11. <https://doi.org/10.1016/j.artd.2015.09.010>.
- [14] Elkins J, Callaghan J, Brown T. The 2014 Frank Stinchfield award: the 'landing zone' for wear and stability in total hip arthroplasty is smaller than we thought: a computational analysis. *Clin Orthop Relat Res* 2014;473:441–52. <https://doi.org/10.1007/s11999-014-3818-0>.
- [15] Biedermann R, Tonin A, Krismser M, Rachbauer F, Eibl G, Stöckl B. Reducing the risk of dislocation after total hip arthroplasty: the effect of orientation of the acetabular component. *J Bone Joint Surg Br* 2005;87-B:762–9. <https://doi.org/10.1302/0301-620X.87B6.14745>.
- [16] Abdel MP, von Roth P, Jennings MT, Hanssen AD, Pagnano MW. What safe zone? The vast majority of dislocated THAs are within the Lewinnek safe zone for acetabular component position. *Clin Orthop Relat Res* 2016;474:386–91. <https://doi.org/10.1007/s11999-015-4432-5>.
- [17] Dorr LD, Malik A, Dastane M, Wan Z. Combined anteversion technique for total hip arthroplasty. *Clin Orthop Relat Res* 2009;467:119–27. <https://doi.org/10.1007/s11999-008-0598-4>.
- [18] Widmer KH, Zurfluh B. Compliant positioning of total hip components for optimal range of motion. *J Orthop Res* 2004;22:815–21. <https://doi.org/10.1016/j.orthres.2003.11.001>.
- [19] Maruyama M, Feinberg JR, Capello WN, D'Antonio JA. The Frank Stinchfield award: morphologic features of the acetabulum and femur: anteversion angle and implant positioning. *Clin Orthop Relat Res* 2001;393:52–65.