

Search...

INTERNET SCIENTIFIC PUBLICATIONS

Navigate...

The Internet Journal of Surgery

Original Article

Percutaneous K-wire Fixation Of Supracondylar Humerus Fractures In Children - Techniques To Minimise Occurrence Of Ulnar Nerve Injuries Through Experiments On Sheep.

L Ashton, J Stephen, R Pattinson, M Solomon, V Mamo, E Bates

Keywords

medicine, percutaneous wire fixation, supracondylar humerus fractures, surgery, ulnar nerve injury

Citation

L Ashton, J Stephen, R Pattinson, M Solomon, V Mamo, E Bates.
Percutaneous K-wire Fixation Of Supracondylar Humerus Fractures In Children - Techniques To Minimise Occurrence Of Ulnar Nerve Injuries Through Experiments On Sheep.. The Internet Journal of Surgery. 2000 Volume 1 Number 2.

Abstract

Ulnar nerve injury following medial wire placement in percutaneous fixation of supracondylar humeral fractures is well recognised. We investigated techniques that may be used to minimise the occurrence and severity of nerve lesions when using percutaneous methods. 4 sheep post euthanasia had K-wires passed through percutaneous nerves before fixation to underlying bone. From our experiments we were able to conclude that the use of sharp wires of

minimum diameter passed perpendicular to the long axis of the nerve before spinning into bone was commenced resulted in minimal nerve injury when compared with our other methods of wire passage.

INTRODUCTION

Ulnar nerve injury following closed reduction and percutaneous K-wire fixation of supracondylar humeral fractures is well documented. Authors have reported the incidence of ulnar nerve injury as ranging from 1.5 - 5.5%^{1,2,3,4} when utilising this technique. By experimental techniques practised on sheep this study investigates methods by which ulnar nerve trauma may be minimised when utilising percutaneous methods.


METHODS

Our investigation involved the use of 4 sheep immediately post euthanasia. The lumbosacral and brachial plexus percutaneous branches were exposed in each limb. Sites along the anatomical path of these nerves were selected which lay directly over bone.

K-wires were then passed through the nerve and fixed to directly underlying bone.

Figure 1

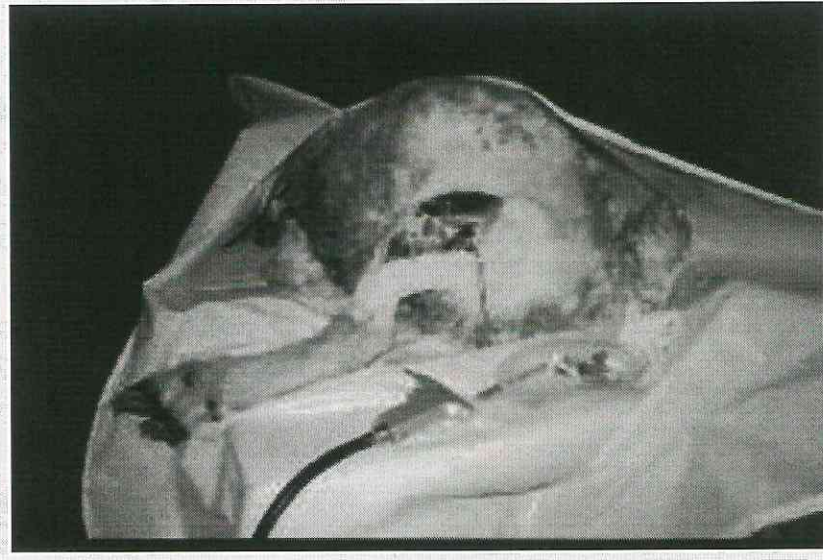Image 1: K-wires



The methods were kept standard by using the same nerve segments in all forelimbs and hindlimbs. Drill speed was kept constant at 800 RPM. Spinning time through nerve and into bone was kept constant at 5 seconds.

Figure 2

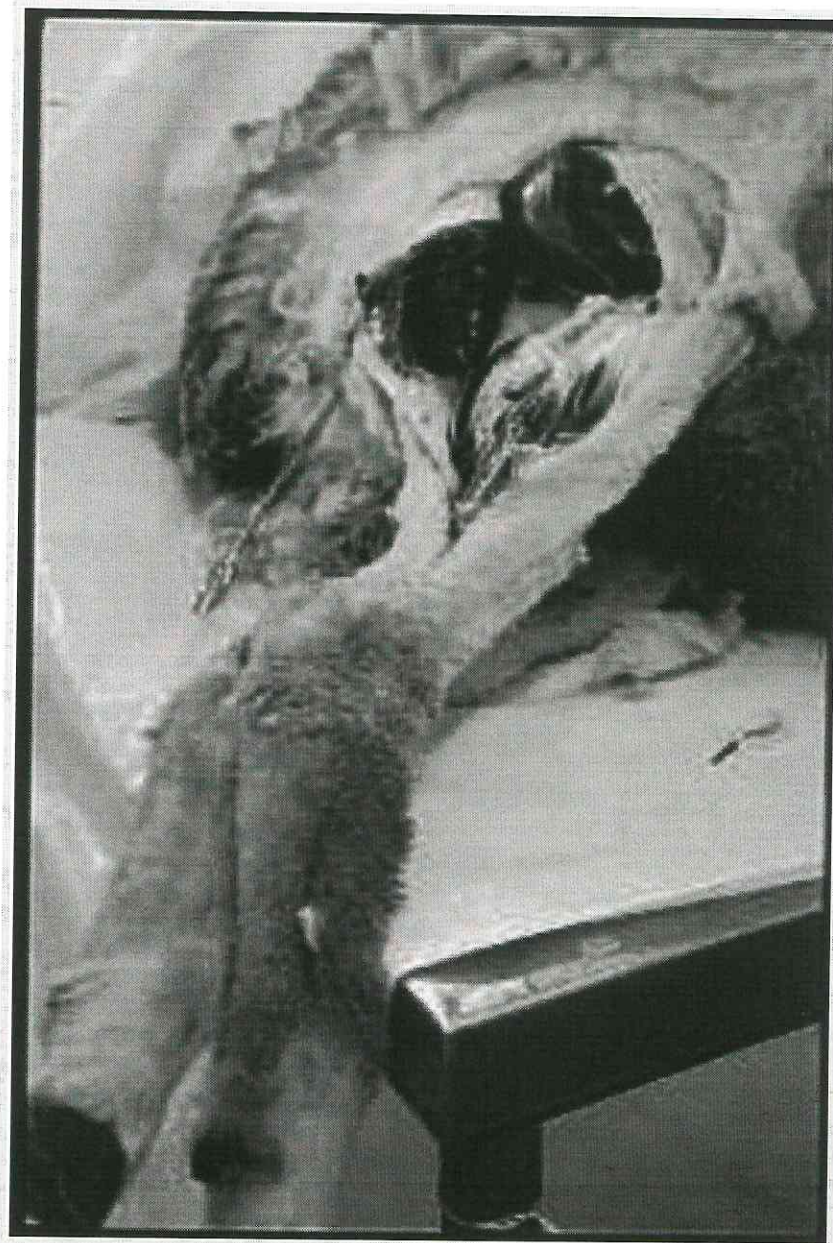Image 2: Lumbosacral plexus exposed



Variables in making our observations concerned the following :

Figure 3

Image 3: K-wire in situ



Segments of nerve with K-wires in situ were then excised and sent for histological examination. Conclusions were drawn from both macroscopic and microscopic data to assess neurological injury.

RESULTS

Observations revealed the following (Table 1):

Figure 4

Image 4: K-wire drilling

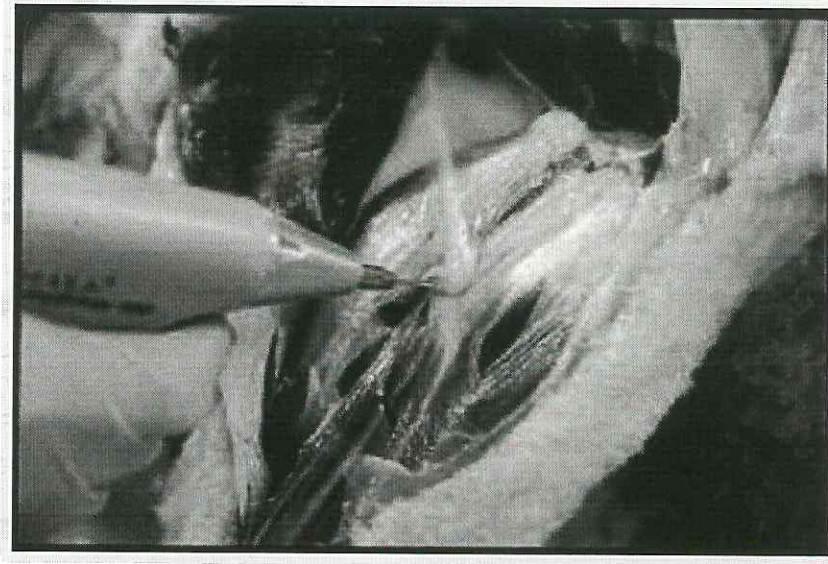


Figure 5

Image 5: Macroscopic neurological injury

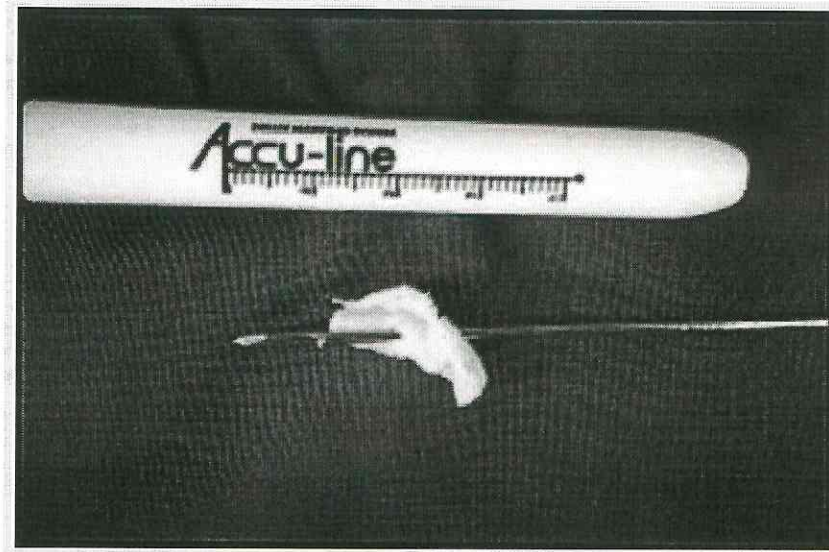


TABLE 1

Macroscopic and Histological Neural damage caused by passage of K-wires.

Associated with minimal damage (contusion within fascicles)

Associated with maximal damage (markedly disrupted fascicles with segmental detachment, perineural separation)

Macroscopic and histological examination allowed us to rank the magnitude of neurological injury in our experiments from least to most as follows:

DISCUSSION

Unfortunately, due to the nature of the study, we were unable to observe clinical neurological deficits caused by the passage of wires. For the same reason histological examination was limited because inflammatory and fibrotic

changes and tissue reactions were unable to be assessed. Notwithstanding, the results of our experiments indicate that certain technical considerations may minimise the extent of ulnar nerve damage when percutaneous methods of fracture stabilisation are used.

The recent literature clearly recommends the use of K-wire fixation to attain and hold accurate reduction and prevent rotational malalignment and cubitus varus. This method was termed by Aronson the "gold standard" approach by which other methods of treatment are to be compared¹. It addresses the 'supracondylar dilemma' as McLaughlin⁵ termed it: severe swelling of the elbow may compromise circulation particularly in the acutely flexed position, however immobilisation in the safe right angle position will frequently result in loss of satisfactory position in an unstable fracture.

Reports by Flynn², Aronson¹, Royce³, and Ikram⁴ reported neurological injury to the ulnar nerve during placement of the medial K-wire. One radial nerve injury was also reported by Royce³ which occurred during placement of the medial wire as it passed through the lateral humeral cortex. These studies quoted frequency of neurological damage to the ulnar nerve as occurring from between 1.5 - 5.5%. All 10 neurological injuries reported in these studies recovered fully within 6 months except for one reported by Aronson¹ which recovered fully by 24 months.

Lyons⁶ concluded that ulnar nerve lesions occurring during medial wire placement had an essentially benign natural history and tended in most cases to resolve, though resolution sometimes took greater than 4 months and was associated with abnormal electromyograms. Such injuries he recommended, should usually be treated by observation alone.

Recommendations in the literature regarding fixation of these fractures in light of the potential for ulnar nerve injury has differed. Kallis⁷ and Arino⁸ recommended the use of two laterally placed wires, thereby avoiding medial wire placement. Certain fracture patterns, however, with significant comminution of the medial humeral cortex require medial fixation for maximal stability. Zions⁹ study carried out on cadavers showed that two crossed pins provided superior resistance to rotational displacement. Ikram⁴ recommended the use of a small incision to locate the median epicondyle and a tissue protecting drill guide to minimise the risk of nerve injury during medial wire placement.

Crossed K-wire fixation is necessary for achieving maximal stability in selected supracondylar fractures. Our institution would recommend a mini - open technique to locate the median epicondyle before passage of the wire under direct vision. Severity of ulnar nerve lesions following incorrect wire placement may be minimised by ensuring wires are sharp tipped and of minimal diameter for fracture stability. Similarly by ensuring direct contact with bone before spinning is commenced and by passing wires perpendicular to the long axis of the nerve, we have found that the severity and risk of causing nerve lesions is decreased.

References

1. Aronson D.C. von Vollenhoven E, Meeuwis J.P K-wire Fixation of Supracondylar Humeral Fractures in Children - Results of open reduction via a ventral approach in comparison with closed treatment. *Injury* 24,3:179-181,

1993

2. Flynn J.C., Matthews J.G., Benott R.L. Blind Pinning of Displaced Supracondylar Fractures of the Humerus in Children. J. Bone and Joint Surgery 56A (2): 263-272, March 1974.
3. Royce R.O. Dutkowsky J.P., Kaiser J.R. and Rand F.R. Neurologic complications after K-wire fixation of Supracondylar Humerus Fractures in Children J Paediatric Orthopaedics, Vol 11, 2: 191-194, 1991
4. Ikram M.A.: Ulnar nerve palsy: a complication following percutaneous fixation of supracondylar fractures of the Humerus in Children. Injury 27 (5) : 303-305, 1996
5. McLaughlin H.L: Trauma: Philadelphia , W.B. Saunders Co 1959
6. Lyons J, Edwin Ashley, Mark Hoffer: Ulnar Nerve Palsies after Percutaneous Cross Pinning of Supracondylar Fractures in Childrens Elbows J Paediatrics Orthopaedics Vol 18: 43-45, 1998
7. Kallis P.E., Foster B.K, Paterson D: Difficult Supracondylar Elbow Fractures in Children Analysis of Percutaneous Pinning Technique J Paediatrics Orthopaedics 12:11, 1992
8. Arino V.L, Lluch E.E. Ramirez A.M. Ferrer J., Rodriguez L, Baixauli F: Percutaneous Fixation of Supracondylar Fractures of the Humerus in Children J Bone and Joint Surgery 59A: 914-6, 1977
9. Zoints L.E. McKellop H.A. Hathaway R: Torsional Strength of Pin Configuration used to fix Supracondylar Fractures of the Humerus in Children J Bone and Joint Surgery 76A: 253, 1994

Author Information

L A Ashton, MD

Sydney Children's Hospital

J.P.H. Stephen, MD

Sydney Children's Hospital

R Pattinson, MD

Sydney Children's Hospital

M Solomon, MD

Sydney Children's Hospital

V Mamo Mamo, MD

Sydney Children's Hospital

E.H. Bates, MD, Professor

Sydney Children's Hospital

[Download PDF](#)

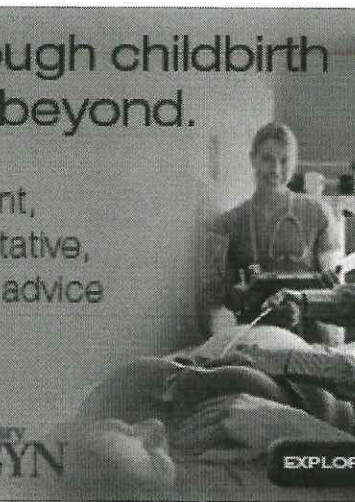
Your free access to ISPUB is funded by the following advertisements:

EXPLORE
2020 PRICES
2019 PRICES

GET IN EARLY >

Through childbirth
and beyond.

Relevant,
authoritative,
expert advice



Contemporary
OB/GYN

EXPLORE NOW

EXPLORE NOW

Contemporary
OB/GYN

Through childbirth and beyond.
Relevant, authoritative, expert advice

[BACK TO TOP](#)